

## LETTERS

### RESEARCH LETTER

# Rarefaction of Blood, But Not Lymphatic Capillaries, in Patients With Cardiac Amyloidosis



Alberto Aimo, MD, PhD,<sup>a,b</sup> Lucrezia Bonino, MD,<sup>c</sup> Vincenzo Castiglione, MD,<sup>a,b</sup> Veronica Musetti, BSc,<sup>b</sup> Martina Rossetti, MD,<sup>d</sup> Alessandra Celi, MD,<sup>d</sup> Michele Coceani, MD,<sup>b</sup> Michele Emdin, MD, PhD,<sup>a,b</sup> Angela Pucci, MD, PhD,<sup>e</sup> Giuseppe Vergaro, MD, PhD<sup>a,b</sup>

The microvasculature plays a critical role in eliminating proteins from the extracellular space. Proteins exit blood capillaries and are subsequently cleared by lymphatic capillaries.<sup>1</sup> The role of cardiac lymphatics in diseases characterized by protein accumulation in the extracellular spaces, such as cardiac amyloidosis (CA),<sup>2</sup> is largely unexplored.

In this study, which was conducted in a CA referral center, we evaluated consecutive left ventricular endomyocardial biopsies (EMBs) from CA patients performed as part of the standard diagnostic work-up (lambda light chains,  $n = 10$ ; kappa light chains,  $n = 2$ ) and 8 with amyloid transthyretin cardiac amyloidosis (ATTR-CA) (all wild type). Endomyocardial samples of consecutive patients who died of trauma and/or cerebral hemorrhage with no cardiac disease at post-mortem examination were also evaluated (controls,  $n = 8$ ). The Institutional Review Board of the University of Pisa approved the study. Samples from EMBs were paraffin embedded. Serial sections were stained with Congo red and Masson trichrome. Immunohistochemistry was performed on adjacent serial sections using the immunoperoxidase technique (HRP Multimer, Ventana Medical Systems, Inc); Ventana Automated Immunostainer System (Roche Diagnostics); and primary antibodies against podoplanin (D2-40, to identify lymphatic vessels; Dako),

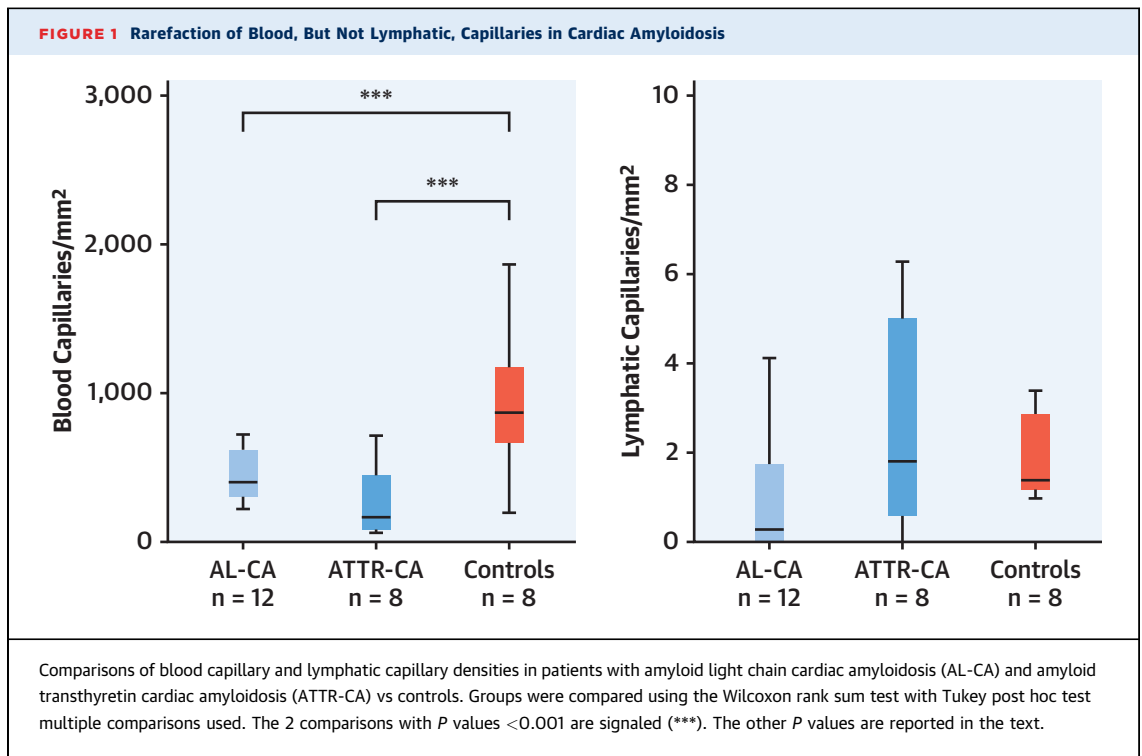
the endothelial marker CD31 (Ventana), kappa and lambda light chains (Ventana), and transthyretin (Dako). Amyloid deposits, transthyretin and light chain immunoreactive deposits, and CD31- and podoplanin-positive capillaries were analyzed using the NIS-Elements computer-assisted image analysis system (Nikon). To ensure that blood and lymphatic capillaries were both captured, we did not perform double immunolabeling because of overlapping CD31 and D2-40 immunostaining, but we compared adjacent sections stained for these antigens. Lymphocytes (CD3+ and CD20+) and monocyte/macrophages (CD68+) were also counted. The total area of biopsy fragments was calculated for each case; total amyloid deposits and total interstitial fibrosis areas were expressed and compared using the Wilcoxon rank sum test.

In CA, amyloid deposits accounted for a median of 14% (Q1-Q3: 10%-19%) in amyloid light chain cardiac amyloidosis (AL-CA) and 19% (Q1-Q3: 10%-30%) in ATTR-CA and fibrosis for 10% in AL-CA (Q1-Q3: 5%-10%) and 10% in ATTR-CA (Q1-Q3: 5%-10%). The extent of amyloid deposits or fibrosis did not differ between AL-CA and ATTR-CA ( $P = 0.38$  and  $0.91$ , respectively). Blood capillary density in patients with either ATTR-CA or AL-CA was lower than in controls (both  $P < 0.001$ ), without differences between ATTR-CA vs AL-CA ( $P = 0.49$ ) (Figure 1). The results

From the <sup>a</sup>Interdisciplinary Center for Health Sciences, Scuola Superiore Sant'Anna, Pisa, Italy; <sup>b</sup>Fondazione Toscana Gabriele Monasterio, Pisa, Italy; <sup>c</sup>University of Pisa, Pisa, Italy; <sup>d</sup>Histopathology Department, Pisa University Hospital, Pisa, Italy; and the <sup>e</sup>Fondazione Pisana per la Scienza ONLUS, San Giuliano Terme, Pisa, Italy.

The authors attest they are in compliance with human studies committees and animal welfare regulations of the authors' institutions and Food and Drug Administration guidelines, including patient consent where appropriate. For more information, visit the [Author Center](#).

Manuscript received March 22, 2024; revised manuscript received July 24, 2024, accepted July 26, 2024.



were consistent when considering blood capillary density outside of the amyloid plaques (AL-CA or ATTR-CA vs controls, both  $P < 0.001$ ; AL-CA vs ATTR-CA;  $P > 0.99$ ). Age was not associated with blood capillary density (ie, CA patients plus controls) ( $P = 0.15$ ).

In patients with AL-CA or ATTR-CA, few lymphatic capillaries were found in the subendocardial layers or adjacent to occasionally present larger intramural blood vessels, mainly represented by arterioles. Regions with extensive amyloid deposits were generally devoid of blood and lymphatic capillaries. Nonetheless, the global density of lymphatic capillaries did not differ in patients with either AL-CA or ATTR-CA vs controls ( $P = 0.59$  and  $P = 0.82$ , respectively) or between AL-CA and ATTR-CA ( $P = 0.14$ ) (Figure 1). The results were also consistent when considering lymphatic vessel density outside of amyloid plaques (data not shown). In controls and in those with AL-CA or ATTR-CA, neither age nor the amount of amyloid or fibrosis was associated with lymphatic capillary density (data not shown).

Our main findings are as follows. First, there is a marked decrease in the density of blood capillaries in patients with CA compared to patients without cardiac disease (controls). Second, no difference in blood

capillary density is observed between patients with amyloid light chain (AL)-type and amyloid transthyretin (ATTR)-type CA. Third, although regions heavily laden with amyloid deposits typically lack both blood and lymphatic capillaries, the overall density of lymphatic capillaries in CA patients (both AL and ATTR types) did not differ from controls.

A recent study assessed for first-time capillary density specifically in AL-CA patients,<sup>3</sup> identifying a higher mortality risk associated with a capillary density  $\leq 220/\text{mm}^2$ . Our study expands on this finding by revealing a similar reduction in capillary density within ATTR-CA patients, with no discernible difference compared to AL-CA. Although age is a risk factor for microvessel rarefaction and CA patients were older than controls, age was not associated with capillary vessel density in our CA patients or controls, suggesting that the lower number of blood capillaries in CA could not be attributed uniquely to the more advanced age of controls. Several mechanisms can be postulated, including inflammation, oxidative stress, and reduced angiogenesis induced by amyloid deposits.<sup>4</sup> In AL-CA, prefibrillary species may cause dysfunction and apoptosis of endothelial cells.<sup>2</sup> Additionally, aggregation of amyloid fibers within the interstitial spaces and increased wall tension from

diastolic dysfunction may promote extrinsic compression and obliteration of blood capillaries.<sup>2</sup> Accumulation of fibrous tissue<sup>5</sup> may also exert extrinsic pressure, contributing to the damage of blood capillaries.

In areas with amyloid deposits, we did not find either blood or lymphatic capillaries. However, lymphatic capillaries were identified in other regions, and the global lymphatic vessel density in AL-CA and ATTR-CA patients did not differ from controls. These observations could have implications for antibody-based therapies targeting AL or ATTR amyloid. Indeed, antibodies might access extracellular spaces through the remaining blood capillaries, and intact lymphatic vessels could support the immune response.

In conclusion, blood vessel density is lower in CA patients than those without cardiac disease. Amyloid deposits are devoid of lymphatic vessels, but the overall density of lymphatic vessels in CA patients is not lower compared to those without cardiac disease.

#### FUNDING SUPPORT AND AUTHOR DISCLOSURES

The authors have reported that they have no relationships relevant to the contents of this paper to disclose.

**ADDRESS FOR CORRESPONDENCE:** Dr Alberto Aimo, Interdisciplinary Center for Health Sciences, Scuola Superiore Sant'Anna, Piazza Martiri della Libertà 33, 56124 Pisa, Italy. E-mail: [a.aimo@santannapisa.it](mailto:a.aimo@santannapisa.it).

#### REFERENCES

1. Brakenhielm E, Alitalo K. Cardiac lymphatics in health and disease. *Nat Rev Cardiol*. 2019;16:56-68.
2. Griffin JM, Rosenblum H, Maurer MS. Pathophysiology and therapeutic approaches to cardiac amyloidosis. *Circ Res*. 2021;128:1554-1575.
3. Kim D, Choi JO, Kim K, et al. Clinical and prognostic implications of capillary density in patients with cardiac light chain amyloidosis. *ESC Heart Fail*. 2021;8:5594-5599.
4. Migrino RQ, Truran S, Gutterman DD, et al. Human microvascular dysfunction and apoptotic injury induced by AL amyloidosis light chain proteins. *Am J Physiol Heart Circ Physiol*. 2011;301:H2305-H2312.
5. Pucci A, Aimo A, Musetti V, et al. Amyloid deposits and fibrosis on left ventricular endomyocardial biopsy correlate with extracellular volume in cardiac amyloidosis. *J Am Heart Assoc*. 2021;10:e020358.

**KEY WORDS** amyloidosis, biopsy, capillary, cardiac amyloidosis, cardiomyopathy, lymphatics, mechanisms, pathophysiology