

# Advances in vascular anatomy and pathophysiology using high resolution and multiparametric sonography

The Journal of Vascular Access  
1–8  
© The Author(s) 2021  
Article reuse guidelines:  
sagepub.com/journals-permissions  
DOI: 10.1177/11297298211020150  
journals.sagepub.com/home/jva  


Petrucci Ilaria<sup>1</sup> , Meola Mario<sup>2</sup> and Fiorina Ilaria<sup>3</sup>

## Abstract

B-mode and Color Doppler are the first-line imaging modalities in cardiovascular diseases. However, conventional ultrasound (US) provides a lower spatial and temporal resolution (70–100 frames per second) compared to ultrafast technology which acquires several thousand frames per second. Consequently, the multiparametric ultrafast platforms manage new imaging algorithms as high-frequency ultrasound, contrast-enhanced ultrasound, shear wave elastography, vector flow, and local pulse wave imaging. These advances allow better ultrasound performances, more detailed blood flow visualization and vessel walls' characterization, and many future applications for vascular viscoelastic properties evaluation.

In this paper, we provide an overview of each new technique's principles and concepts and the real or potential applications of these modalities on the study of the artery and venous anatomy and pathophysiology of the upper limb before and after creating a native or prosthetic arterio-venous fistula. In particular, we focus on high-frequency ultrasound that could predict cannulation readiness and its potential role in the venous valvular status evaluation before vascular access creation; on contrast-enhanced ultrasound that could improve the peri-operative imaging evaluation during US-guided angioplasty; on shear wave elastography and local pulse wave imaging that could evaluate preoperative vessels stiffness and their potential predictive role in vascular access failure; on vector flow imaging that could better characterize the different components of the vascular access complex flow.

## Keywords

Multiparametric ultrasound, shear wave elastography, high-frequency ultrasound, vector flow imaging, local pulse wave velocity, vascular access

Date received: 19 June 2020; accepted: 6 May 2021

## Introduction

Ultrasound (US) is the first-line imaging modality for screening, diagnosis, and monitoring treatment in cardio-circulatory pathology because of its safeness, non-invasiveness, wide availability, and low cost. Conventional ultrasound modalities as B-mode, color Doppler, and spectral analysis allow the recognition of vessel wall and bloodstream changes, depicting the site of vascular stenoses and occlusions.<sup>1,2</sup> Consequently, US plays a pivotal role also in hemodialysis vascular access creation and surveillance.

Conventional platforms have a limited frame rate (images/second) because they use the line-by-line scanning acquisition method. This technical approach provides a limited temporal resolution. Recent ultrafast platforms acquire

image information at frame rates of several thousand Hz, while conventional ultrasound systems acquire images at only 70–100 frames per second. The higher temporal and spatial resolution of this technical approach allows managing all the new imaging algorithms as high-frequency

<sup>1</sup>Institute of Life Sciences, S. Anna School of Advanced Studies, Pisa, Italy

<sup>2</sup>Institute of Life Sciences, S. Anna School of Advanced Studies, Department of Internal Medicine, University of Pisa, Pisa, Italy

<sup>3</sup>Radiodiagnostic and Interventional Radiology Department, Fondazione IRCCS Policlinico San Matteo, Pavia, Italy

### Corresponding author:

Petrucci Ilaria, Institute of Life Sciences, S. Anna School of Advanced Studies, Piazza Martiri della Libertà, 33, Pisa 56127, Italy.  
Email: i.petrucci@santannapisa.it

ultrasound (HFUS), contrast-enhanced ultrasound (CEUS), shear wave elastography, vector flow, and local pulse wave imaging. Ultrafast imaging allows better US performance, with more detailed visualization of blood flow, better characterization of vessel walls, and many applications in vascular viscoelastic properties evaluation.

The availability of these technologies allows coining the term “high resolution” and “multiparametric ultrasound” (MPUS) to define the current imaging applications on the top-line machine.<sup>3</sup>

Regarding vascular applications, the technological advances with potential applications in vascular access planning and surveillance are HFUS, CEUS, shear wave elastography, vector flow, and local pulse wave imaging.<sup>3–5</sup>

In this paper, we provide an overview of the principles and concepts of high resolution and MPUS, and we describe the actual or potential applications on the study of the artery and venous anatomy and pathophysiology of the upper limb before and after the creation of a native arteriovenous fistula (AVF) or a graft.

## High-frequency ultrasound

High-frequency ultrasound refers to the US probe frequency of more than 10 MHz. High-frequency transducers were introduced in the pre-clinical setting and were mainly used in animal models to monitor tumor growth and to evaluate changes in micro-vascularization of neoplastic masses after antineoplastic therapy.<sup>4</sup> The US transducers used in clinical practice operate at 22–100 MHz. These frequencies have short wavelengths and are more easily absorbed, so they improve spatial resolution with a reduced depth of penetration. HFUS could be applied to evaluate normal and diseased skin and superficial vessels.

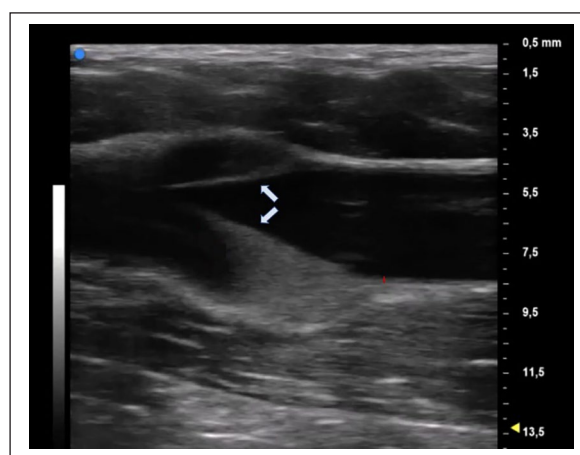
### Clinical applications

Nowadays, HFUS is used in neonatal and pediatric pathologies to evaluate nerves, hand transplants, thyroid, lymph nodes, male reproductive organs, dermatological pathologies (melanoma, lipoma, hair follicles), and also musculoskeletal and oral pathologies.<sup>6</sup>

The vascular applications of this technique are mainly on the smallest vascular anatomy: arteries and veins in pediatric and neonatal patients, measurement of Intima-Media Thickness (IMT) and characterization of carotid plaques for research and assessment of cardiovascular health, assessment of peripheral vessels in diabetes and other circulatory condition and visualization of flow patterns in atherosclerotic or abnormal vessels.

### Vascular access applications

Jaberi et al.<sup>7</sup> have hypothesized that venous wall thickness and circumferential stress measured with HFUS could



**Figure 1.** Cephalic vein valve and IMT evaluated with HFUS. Valve flaps are very well distinguishable (white arrows) and IMT (red line) is measurable at the far wall of the vessel.

predict cannulation readiness in AVFs. They have scanned an excised AVF specimen with a 55-MHz probe, and they have correlated the US findings with histological features. Then, they measured with HFUS the IMT of the near-field AVF venous wall of 20 patients with newly created AVFs within one week of cannulation. Cannulation readiness was defined as no extravasation during the first dialysis treatment. The mean IMT of the no extravasation group was greater than that of the extravasation group ( $p < 0.001$ ). A minimum threshold IMT of 0.13 mm ( $p < 0.001$ ) was associated with successful cannulation. The mean circumferential stress of the no extravasation group was lower than that of the extravasation group ( $p < 0.001$ ). A maximum circumferential stress threshold of 248 kPa was associated with successful cannulation ( $p = 0.009$ ). They concluded that venous IMT and circumferential stress assessed with HFUS could predict cannulation readiness in AVFs clinically considered mature.

High-frequency US could also be useful in evaluating venous valves (Figure 1) during the preoperative mapping before AVF creation, and further studies are needed to evaluate its real utility.

## Contrast-enhanced ultrasound

CEUS is an imaging modality based on microbubbles, made up of a hydrophilic shell surrounding a gas core, using their property of resonant volumetric oscillations in response to the acoustic pressure variations of the ultrasound waves.

Ultrasound contrast enhancers are administered intravenously in an aqueous solution as a bolus followed by a flush saline solution. Microbubbles have a mean size of 3  $\mu\text{m}$ , and in general 95% of the bubbles pooling is smaller than 10  $\mu\text{m}$ . They remain in the bloodstream, do not pass into the interstitial fluid and easily cross the pulmonary

and peripheral capillaries without causing thrombotic complications. They are able to make “bright” the vessel, allowing an accurate study of the micro and macro-vasculature.<sup>8</sup> Microbubbles are then disrupted by the acoustic US pulse and exhaled with breathing. CEUS imaging permits the evaluation of the vascular abnormalities, estimates blood flow parameters, and identifies and quantifies the neovascularization.<sup>9,10</sup>

### *Clinical applications*

In literature, the use of CEUS has recently obtained many established and emerging applications.<sup>11</sup> CEUS is routinely employed for the differential diagnosis in focal parenchymal lesions, especially in the liver and in the kidney, for screening and early diagnosis of hepatocellular carcinoma in cirrhotic livers.<sup>12</sup> Microbubbles allow to assess of the contrast enhancement due to malignant angiogenesis and identify the “wash-out” in the late phases.

CEUS imaging is also used to evaluate abdominal aortic aneurysm after endovascular aneurysm repair as an alternative to computed tomography angiography, especially in contrast allergy or in patients with impaired renal function avoid excessive radiation exposure during follow-up.<sup>13</sup> CEUS can accurately detect and characterize eventual endoleak, showing the persistence of contrast enhancement into the aneurysmal sac, which may lead to progressive aneurysmal enlargement and secondary rupture. CEUS is even superior to tomography angiography to detect the presence and type of endoleaks in some cases. It is not affected by metallic artifacts of the graft, and it is a dynamic imaging modality allowing to visualize the inflow vessels source of endoleak. Limitations are similar to conventional US imaging: operator dependence and image quality impairment depending on body habitus and bowel gas presence.<sup>14</sup> The risk of anaphylactic reaction after ultrasound contrast agent administration is very rare (1 on 100.000 cases).

CEUS imaging is also spreading in the Emergency Department, where this method permits the identification of aortic dissection and post-traumatic parenchymal injuries and finds eventual focal sources of bleeding.<sup>15</sup>

CEUS imaging allows an accurate measurement of the degree and length of stenosis and better evaluates plaque morphology, thickness, and vulnerability. For these reasons, many studies applied this imaging modality to assess the extracranial carotid occlusive disease and estimate the carotid plaque. It was demonstrated the possibility to detect and quantify intraplaque angiogenesis, which is a marker of plaque growth.<sup>16</sup> Thus, CEUS may be used for risk stratification of patients with atherosclerotic disease and predict the risk of cerebrovascular accident.

### *Vascular access applications*

Ramnarine et al.<sup>17</sup> reported the use of CEUS in 11 patients in ultrasound guided AVFs balloon angioplasty procedures

for failing or non-maturing AVFs. The procedure was under the guidance, and CEUS was used initially to evaluate the fistula morphology and after balloon angioplasty to confirm the stenosis treatment and reveal intra-operative complications. They conclude that CEUS improves peri-operative imaging evaluation because it provides a higher spatial resolution for narrow stenotic segments. It is more sensitive in demonstrating potential complicating extravasation, avoiding the use of iodinated contrast, and being a viable alternative to fluoroscopy for AVF intervention. The main limitations are that more proximal lesions may be difficult to visualize due to depth limitation.

### **Tissue elastography**

Mechanical tissue properties change in many different disease processes that lead to fibrosis, inflammation, and neovascularization. US elastography evaluates the tissue stiffness based on Young’s modulus, a physical property that relates applied force per unit area (stress) and the consequent relative change in tissue dimension (strain). Ultrasonographic methods to evaluate tissue elastography may be strain-based, in which the probe pressure applies the force, or shear wave-based, in which the force is produced by the imaging system.<sup>18</sup> Strain elastography only allows semi-quantitative assessments of stiffness that are difficult to compare longitudinally. Shear wave propagation velocity is directly correlated with tissue stiffness, and in most ultrasound systems, compressive acoustic waves are used to induce and track shear waves all along with the ultrasound probe, permitting shear wave velocity estimation.

US elastography has been successfully applied to evaluate many tissues and organs, including liver, breast, thyroid, kidney, spleen, prostate, lymph nodes, tendons, and vessels.<sup>18,19</sup>

### *Clinical applications*

Strain elastography is an accurate technique to distinguish liver fibrosis stages and benign from malignant liver masses. Shear wave elastography (SWE) is used since the early stages of liver fibrosis caused by HBV, HCV, alcoholic liver disease, hepatic toxicity, and autoimmune hepatitis. In patients with chronic kidney disease (CKD), strain values are higher than in healthy volunteers, and strain elastography can also detect early renal graft interstitial fibrosis, suggesting an organ rejection. SWE has shown significant differences between CKD grades, and it could also represent a marker for diabetic kidney disease.<sup>18</sup> Moreover, strain-imaging studies to assess focal renal masses have shown promising results. SWE has improved the differential diagnosis between benign and malignant breast, thyroid, pancreas, and prostate lesions, and encouraging results are growing about the use of SWE in the differential diagnosis between benign and malignant lymph nodes, endoscopic spleen evaluation in chronic liver

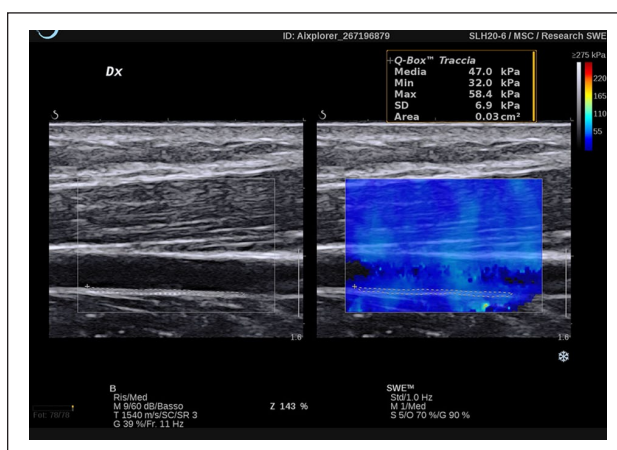
disease, and cirrhosis.<sup>19</sup> The cardiovascular system is a new potential field of application of SWE, especially in the risk stratification of carotid plaques<sup>3</sup> and in the evaluation of carotid stiffness in patients with acute ischemic stroke.<sup>20</sup> Arterial stiffness measured with SWE has been evaluated in patients with CKD, and the results show that their brachial artery is stiffer than in healthy subjects.<sup>21</sup> At present, there is only limited evidence available for the application of SWE in the evaluation of peripheral veins, in particular on thrombus characterization.<sup>3</sup>

### Vascular access applications

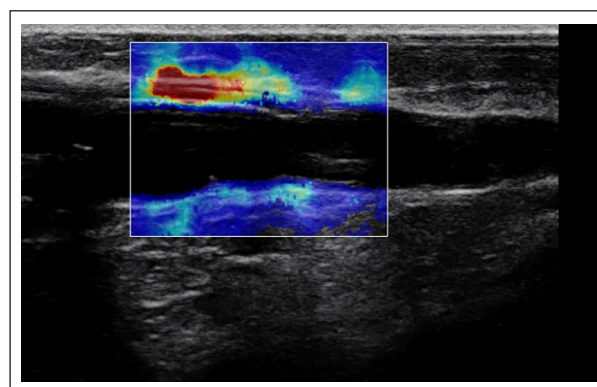
Inabilities to prevent non-maturation or avoid early failure of AVFs are due to an incomplete understanding of preexisting arterial and venous conditions. Small-diameter at anastomosis sites, old age, diabetes mellitus, arteriosclerotic pathologies of the artery, and preexisting low-quality vein wall are all risk factors of non-maturation and early failure of vascular access.<sup>22</sup> Whether preexisting vascular pathologies associated with or aggravated by CKD can impair the necessary adaptive remodeling of blood vessels after vascular access placement is still an open question. There is some evidence that the elastic modulus measurements are significantly higher in patients undergoing preoperative mapping for hemodialysis access than in healthy volunteers.<sup>23</sup> The arterial stiffness could be a possible biomarker for AVF failure due to the lower arterial ability to dilate.<sup>24–26</sup> However, the studies published to date on the arterial stiffness evaluation before or after AVFs creation are not conclusive because they have used very heterogeneous methods, not including SWE that could potentially be able to evaluate the local arterial stiffness.<sup>27–29</sup> MacDonald et al.<sup>30</sup> have retrospectively analyzed the preoperative and postoperative data of 33 patients indicated for fistula creation. Vessels diameters at the B-mode ultrasound, SWE of the brachial artery, and demographic data were considered to find if any of these variables were related to the outcome of the AVF 3 months after creation. Shear wave velocity decreased after AVF creation, indicating increased compliance, but there were no parameters associated with AVF failure. Further studies with a larger number of patients and a longer follow-up period are needed to assess the utility of SWE evaluation of arterial and or venous vessels before and after AVF (Figure 2) or AVG creation (Figure 3).

### Vector flow imaging

Vector Flow Imaging (VFI) is an innovative imaging algorithm, angle-independent, which provides a multidimensional characterization of blood flow in all directions, showing the streamlines and vortices distribution into a vessel as velocity vectors.<sup>31</sup>



**Figure 2.** Longitudinal view of a cephalic vein in a distal radio-cephalic AVF using local SWE. The region of interest is adjusted to the IMT of the far wall of the vein. In this case the venous IMT is homogeneous with a stiffness of 47 kPa.



**Figure 3.** Longitudinal view of the venous anastomosis in a prosthetic arteriovenous fistula using SWE, which shows the different elastic properties and stiffness of the vessel walls. The portion of the graft is much stiffer (represented in red) at the venous anastomosis than the contiguous venous walls.

Commercial US systems primarily developed two methods of estimation based on different principles: transverse oscillation method and plane wave imaging. In the transverse oscillation method, the probe emits several consecutive pulses. Two receiving beamformers are used to estimate the axial and transverse components of the velocity vectors, and the difference from the received signals is compared to calculate the velocity.<sup>32,33</sup>

In ultrafast plane wave imaging, the transmission is made up of single unfocused beams at several incidence angles. The multidirectional flow estimation is performed through speckle tracking, and the real vector velocity is calculated by compounding velocities returning from a series of steers through a complex angle-compounding algorithm.<sup>34–36</sup>



These methods allow a high frame rate, with a dynamical and intuitive visualization of complex hemodynamic features. The bloodstream is represented in VFI with many moving-colored arrows, where the color and the length of the vector indicate the velocity magnitude.<sup>37</sup> The operator can measure the velocity at any point of the vessel and every instant of the cardiac cycle, revealing even transient flow movements, otherwise not detectable with conventional ultrasound.

VFI has some limitations. It is based on pulse repetition frequencies, so it does not permit the correct measurements of higher velocities in aliasing areas, and it is a two-dimensional technique, not allowing a 3-D comprehension of the streamlines.

### Clinical applications

Several clinical studies based on VFI showed the additional information carried out from this technique analyzing different flow patterns in the human cardio-circulatory system.

The first in-vivo study with the vector velocity method, based on plane wave acquisition, was published in 2009 by Hansen et al.,<sup>38</sup> which reported the visualization of a stable vortex in the bulb of six carotid bifurcations.

VFI was then deployed to demonstrate reversal blood flow from the external to the internal carotid during the systole, suggesting the possible role of retrograde embolism in the case of plaques in the proximal external carotid artery.<sup>39</sup>

Goddi et al.<sup>37</sup> evaluated 60 carotid bifurcations in healthy adults, identified a complex flow in the internal carotid artery, and analyzed the location and the duration of the different blood flow patterns, confirming the relationship between vessel enlargement and flow disturbances. VFI was also used to assess the normal values of wall shear stress in the common carotid arteries of 79 healthy volunteers, with a good intraclass correlation coefficient and inter-observer reproducibility.<sup>40</sup>

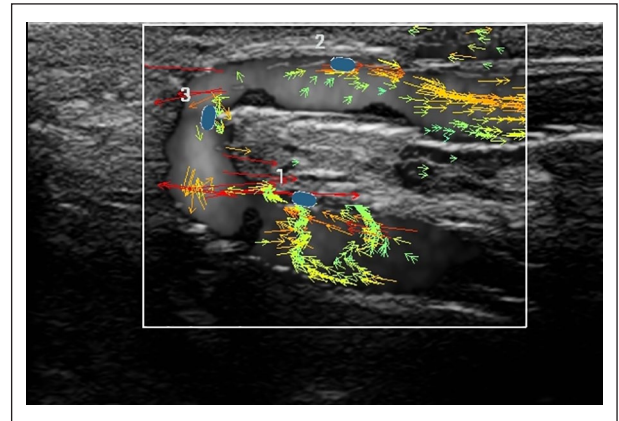
Hansen et al.<sup>41</sup> demonstrated the association between the vector concentration in VFI and the stenosis degree percentage obtained with digital subtraction angiography in 11 patients with stenoses of the superficial femoral artery.

In a rare case of the femoral artery “trifurcation,” where the origin of the lateral circumflex femoral artery arises from the femoral bifurcation, VFI revealed a blood recirculation rest and retrograde blood flow redistribution during lower limb compression.<sup>42</sup>

These preliminary evaluations demonstrate that high frame rate VFI represents an innovative ultrasound application, with a better and more intuitive flow estimation within the vessel during the cardiac cycle.

### Vascular access applications

Hansen et al.<sup>43</sup> compared the blood flow volume measured during dialysis sessions with VFI and the ultrasound



**Figure 4.** Longitudinal view of a radio-cephalic fistula using VFI, which represents the flow with many colored vectors frame. In this frame at the systolic peak it shows high velocity red vectors at the arterial side just before the fistula anastomosis, with recirculation and reverse flow (1), multidirectional low-velocity green vector against the venous wall on the venous side of the anastomosis (3) and faster vector streamline at the venous side of the fistula (2).

dilation technique in 20 AVFs, evidencing a good correlation with these methods. The possible sources of error during the volume flow rate measurement with VFI are related to the off-axis placement of the scan plane compared to the vessel’s central axis.<sup>44</sup>

A recent study reported the use of VFI in 14 AVFs to identify the different components that compound a complex flow (Figure 4). The authors found the presence of a disturbed flow, probably related to oscillatory wall shear stress and neointimal hyperplasia development, at the inner wall of the juxta-anastomotic venous side, into the venous aneurysmal tracts and in concomitance of stenosis.<sup>45</sup>

### Pulse wave velocity measurement

Arterial stiffness is a predisposing factor for peripheral vascular disease and represents, in atherosclerosis, an independent risk marker for cardiovascular disease.<sup>46</sup> Arterial stiffness can be measured with many different methods, but pulse wave velocity (PWV) is considered the most reliable. PWV is the velocity at which the blood pressure pulse propagates through the circulatory system.<sup>47</sup> The carotid-femoral PWV is accepted as the standard for measuring aortic stiffness based on a “propagation model” of the arterial tree. However, it has several limitations because it needs a dedicated device, the measurement is not easily feasible and repeatable, and, finally, it does not assess a local arterial stiffness difference.<sup>48</sup> Two novel techniques are currently being evaluated for PWV measurement: SWE, treated in a previous section, and ultrafast ultrasound imaging or UltraFastEcho (or UltraFast® Imaging), which measures the local PWV at the beginning

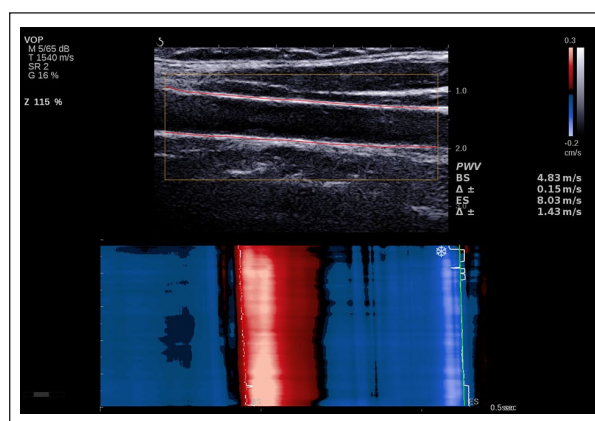
and the end of systole.<sup>48</sup> The technological innovation is based on the extremely high imaging frame rate, which is one hundred times faster than conventional ultrasound diagnostic imaging, thus capturing the propagation of the pulse wave in a localized segment of an artery during a single cardiac cycle. The evaluation of local PWV has become an important tool because local PWV has emerged as a powerful independent predictor of all-cause and cardiovascular mortalities.<sup>5</sup>

### Clinical applications

Many studies in the literature have proven that global PWV is a predictor of all causes and cardiovascular causes of death in the general population.<sup>49</sup> In CKD, the arterial stiffness measured with global PWV is worse in diabetic compared with no diabetic patients. PWV worsens as kidney function declines irrespective of the cause of CKD. It correlates with proteinuria in CKD diabetic patients and bone and mineral disorders. PWV is associated with higher central pulse pressures and predicts the onset of heart failure, death, and CKD progression to end-stage renal disease.<sup>50</sup> Currently, local PWV measurements are being studied in order to provide localized information on arterial stiffness in many fields, such as vessel elasticity abnormalities of individual target arteries and the prediction of cardiovascular events and end-organ damage, classification of normal and pathological arteries in hypertensive patients, assessment of coronary artery hemodynamics and determination of acute coronary events, non-invasive assessment of fetal hemodynamics, characterization of the retinal and ocular circulation analysis, and assessment of microvascular stiffness.

### Vascular access applications

The role of PWV measurement in vascular access evaluation is not encouraging in literature. In the Hemodialysis Fistula Maturation Study on 602 patients undergoing AVF creation, Dember et al.<sup>29</sup> that there is a low correlation between global PWV measurement and demographic, clinical, and biochemical factors among the different vascular function measures. Allon et al.,<sup>51</sup> in the same group of patients, have stated that despite the hypothesis for which the stiffness of the arterial conduit used to create the AVF would restrict arterial outward remodeling, the study failed to find such a relationship. The carotid-femoral PWV showed an inverse relationship with 6-week AVF diameter, but there were no statistically significant relationships between carotid-femoral PWV/carotid-radial PWV and AVF blood flow. Masengu et al.<sup>26</sup> and McGrogan et al.<sup>52</sup> did not find any statistically significant association between carotid-femoral PWV, brachial-radial PWV, and AVF early failure. However, in the second study, the aortic



**Figure 5.** Ultrafast measurement of the local PWV of the brachial artery. Ultrafast PWV measurements are obtained at the beginning of systole (BS) and the end of systole (ES). The region of interest is adjusted to the entire field of view of the transducer.

PWV was slower in the primary patency group than the primary failure group, suggesting that stiffer vessels lead to a higher probability of AVF primary failure.

In any case, in all studies, the techniques used for PWV evaluation represent indirect measures of arterial stiffness and are influenced by the global evaluation of several different arteries that may differ in their stiffness. Consequently, local PWV measurement could represent a direct evaluation of brachial and radial artery stiffness (Figure 5). For this reason, it would be very interesting to perform studies on the preoperative evaluation of local arterial stiffness before AVF creation and the correlation with AVF outcomes.

### Conclusion

The technological advances encompassed in MPUS have many potential and interesting applications in vascular access planning and surveillance, and only a few of them have already been successfully applied. However, studies with many patients are needed to standardize the parameters for the study of the upper limb vascular anatomy and physiopathology before and after AVF/AVG creation and to evaluate their potential correlation with vascular access outcomes.


### Declaration of conflicting interests

The author(s) declared no potential conflicts of interest with respect to the research, authorship, and/or publication of this article.

### Funding

The author(s) received no financial support for the research, authorship, and/or publication of this article.

**ORCID iD**

Petrucci Iliaria  <https://orcid.org/0000-0003-1931-1581>

**References**

- Rubi JM. Spectral Doppler US. *Radiographics* 1994; 14: 139–150.
- Bude RO and Rubi JM. Power Doppler sonography. *Radiology* 1996; 200: 21–23.
- Rafailidis V and Sidhu PS. Vascular ultrasound, the potential of integration of multiparametric ultrasound into routine clinical practice. *Ultrasound* 2018; 26(2): 136–144.
- Shung K, Cannata J, Qifa Zhou M, et al. High frequency ultrasound: a new frontier for ultrasound. In: *2009 annual international conference of the IEEE engineering in medicine and biology society*, Minneapolis, MN, 3–6 September 2009, pp.1953–1955. New York: IEEE.
- Nabeel PM, Raj Kiran V, Joseph J, et al. Local pulse wave velocity: theory, methods, advancements, and clinical applications. *IEEE Rev Biomed Eng* 2020; 13: 74–112.
- Izzetti R, Vitali S, Oranges T, et al. Intraoral Ultra-High Frequency Ultrasound study of oral lichen planus: a pictorial review. *Skin Res Technol* 2020; 26(2): 200–204.
- Jaberi A, Muradali D, Marticorena RM, et al. Arteriovenous fistulas for hemodialysis: application of high-frequency US to assess vein wall morphology for cannulation readiness. *Radiology* 2011; 261: 616–624.
- Feinstein SB. The powerful microbubble: from bench to bedside, from intravascular indicator to therapeutic delivery system, and beyond. *Am J Physiol Heart Circ Physiol* 2004; 287: 450–457.
- Dietrich CF, Averkiou MA, Correias JM, et al. An EFUSMB introduction into dynamic contrast-enhanced ultrasound (DCE-US) for quantification of tumour perfusion. *Ultraschall Med* 2012; 33: 344–351.
- Shah F, Balan P, Weinber M, et al. Contrast-enhanced ultrasound imaging of atherosclerotic carotid plaque neovascularization: a new surrogate marker of atherosclerosis? *VascMed* 2007; 12: 291–297.
- Sidhu PS, Cantisani V, Dietrich CF, et al. The EFSUMB guidelines and recommendations for the clinical practice of contrast-enhanced ultrasound (CEUS) in non-hepatic applications: update 2017. *Ultraschall Med* 2018; 39(2): e2–e44.
- D’Onofrio M, Crosara S, De Robertis R, et al. Contrast-enhanced ultrasound of focal liver lesions. *Am J Roentgenol* 2015; 205(1): W56–W66.
- Partovi S, Kaspar M, Aschwanden M, et al. Contrast-enhanced ultrasound after endovascular aortic repair-current status and future perspectives. *Cardiovasc Diagn Ther* 2015; 5: 454–463.
- Bendick PJ, Bove PG, Long GW, et al. Efficacy of ultrasound scan contrast agent in the noninvasive follow-up of aortic stent grafts. *J Vasc Surg* 2003; 37: 381–385.
- Kummer T, Oh L, Phelan MB, et al. Emergency and critical care applications for contrast-enhanced ultrasound. *Am J Emerg Med* 2018; 36: 1287–1294.
- Faggioli GL, Pini R, Mauro R, et al. Identification of carotid “vulnerable plaque” by contrast-enhanced ultrasonography: correlation with plaque histology, symptoms and cerebral computed tomography. *Eur J Vasc Endovasc Surg* 2011; 41: 238–248.
- Ramnarine R, Freedman B, Navaratne S, et al. Novel use of contrast enhanced ultrasound (CEUS) in angioplasty of haemodialysis arteriovenous fistulas: initial experience. *ECR* 2013; C–2530.
- Ozturk A, Grajo JR, Dhyani M, et al. Principles of ultrasound elastography. *Abdom Radiol* 2018; 43: 773–785.
- Sigrist RMS, Liau J, El Kaffas A, et al. Ultrasound elastography: review of techniques and clinical applications. *Theranostics* 2017; 7: 1303–1329.
- Li Z, Du L, Wang F, et al. Assessment of the arterial stiffness in patients with acute ischemic stroke using longitudinal elasticity modulus measurements obtained with shear wave elastography. *Med Ultrason* 2016; 18: 182–189.
- MacDonald C, Ross R and Houston JG. Shear wave velocity measurements of the brachial artery in a population with end-stage renal disease. *Biomed Phys Eng Express* 2018; 4: 057002.
- Vazquez-Padron RI and Allon M. New insights into dialysis vascular access: impact of preexisting arterial and venous pathology on AVF and AVG outcomes. *Clin J Am Soc Nephrol* 2016; 11: 1495–1503.
- Sorace AG, Robbin ML, Umphrey H, et al. Ultrasound measurement of brachial artery elasticity prior to hemodialysis access placement: a pilot study. *J Ultrasound Med* 2012; 31(10): 1581–1588.
- McGrogan DG, Maxwell AP, Khawaja AZ, et al. Current tools for prediction of arteriovenous fistula outcomes. *Clin Kidney J* 2015; 8: 282–289.
- Kheda MF, Brenner LE, Patel MJ, et al. Influence of arterial elasticity and vessel dilatation on arteriovenous fistula maturation: a prospective cohort study. *Nephrol Dial Trans* 2010; 25: 525–531.
- Masengu A, Hanko JB and Maxwell AP. Arterial stiffness and arteriovenous fistula failure of maturation. *J Vasc Access* 2016; 17: 477–482.
- Weitzel WF, Kim K, Park DW, et al. High-resolution ultrasound elasticity imaging to evaluate dialysis fistula stenosis. *Semin Dial* 2009; 22: 84–89.
- Paulson WD. Does vascular elasticity affect arteriovenous fistula maturation? *Open Urol Nephrol J* 2014; 7: 26–32.
- Dember LM, Imrey PB, Duess MA, et al. Vascular function at baseline in the hemodialysis fistula maturation study. *J Am Heart Assoc* 2016; 5(7): e003227.
- MacDonald CJ, Ross R and Houston JG. Increased brachial artery compliance after arteriovenous fistula creation as measured by shear wave elastography. *J Ultrasound Med* 2020; 39(5): 875–881.
- Goddi A, Bortolotto C, Fiorina I, et al. High-frame rate vector flow imaging of the carotid bifurcation. *Insights Imaging* 2017; 8: 319–328.
- Udesen J and Jensen JA. Investigations of transverse oscillation methods. *IEEE Trans Ultrason Ferroelectr Freq Control* 2006; 53: 959–971.
- Udesen J, Nielsen MB, Nielsen KR, et al. Examples of *in vivo* blood vector velocity estimation. *Ultrasound Med Biol* 2007; 33: 541–548.
- Yiu BY, Lai SS and Yu AC. Vector projectile imaging: time-resolved dynamic visualization of complex flow patterns. *Ultrasound Med Biol* 2014; 40: 2295–2309.
- Ekroll IK, Dahl T, Torp H, et al. Combined vector velocity and spectral Doppler imaging for improved imaging of

- complex blood flow in the carotid arteries. *Ultrasound Med Biol* 2014; 40: 1629–1640.
36. Ricci S, Bassi L and Tortoli P. Real-time vector velocity assessment through multigate Doppler and plane waves. *IEEE Trans Ultrason Ferroelectr Freq Control* 2014; 61: 314–324.
  37. Goddi A, Fanizza M, Bortolotto C, et al. Vector flow imaging techniques: a new way to study vessel flow with ultrasound. *J Clin Ultrasound* 2017; 45: 582–588.
  38. Hansen KL, Udesen J, Gran F, et al. In-vivo examples of flow patterns with the fast vector velocity ultrasound method. *Ultraschall Med* 2009; 30: 471–477.
  39. Meyer P and Pelz JO. Blood flow reversal from the external into the internal carotid artery—new insights into the hemodynamics at the carotid bifurcation. *Brain Behav* 2018; 8: e01139.
  40. Qiu Y, Yang D, Zhang Q, et al. V Flow technology in measurement of wall shear stress of common carotid arteries in healthy adults: feasibility and normal values. *Clin Hemorheol Microcirc* 2020; 74(4): 453–462.
  41. Hansen KL, Hansen PM, Ewertsen C, et al. Vector flow imaging compared with digital subtraction angiography for stenosis assessment in the superficial femoral artery – a study of vector concentration, velocity ratio and stenosis degree percentage. *Ultrasound Int Open* 2019; 5: E53–E59.
  42. Au JS, Yiu BJS and Yu ACH. Case studies in physiology: visualization of blood recirculation in a femoral artery “trifurcation” using ultrasound vector flow imaging. *J Appl Physiol (1985)* 2019; 127: 1809–1813.
  43. Hansen PM, Olesen JB, Pihl MJ, et al. Volume flow in arteriovenous fistulas using vector velocity ultrasound. *Ultrasound Med Biol* 2014; 40: 2707–2714.
  44. Jensen J, Olesen JB, Stuart MB, et al. Vector velocity volume flow estimation: sources of error and corrections applied for arteriovenous fistulas. *Ultrasonics* 2016; 70: 136–146.
  45. Fiorina I, Raciti MV, Goddi A, et al. Ultrasound vector flow imaging – could be a new tool in evaluation of arteriovenous fistulas for hemodialysis? *J Vasc Access* 2017; 8: 284–289.
  46. Van Bortel LM, Laurent S, Boutouyrie P, et al. Expert consensus document on the measurement of aortic stiffness in daily practice using carotid- femoral pulse wave velocity. *J Hypertens* 2012; 30: 445–448.
  47. Luo J, Li RX and Konofagou EE. Pulse wave imaging of the human carotid artery: an *in vivo* feasibility study. *IEEE Trans Ultrason Ferroelectr Freq Control* 2012; 59: 174–181.
  48. Messas E, Pernotb M and Couade M. Arterial wall elasticity: state of the art and future prospects. *Diagn Interv Imaging* 2013; 94: 561–569.
  49. Ben-Shlomo Y, Spears M, Boustred C, et al. Aortic pulse wave velocity improves cardiovascular event prediction: an individual participant meta-analysis of prospective observational data from 17,635 subjects. *J Am Coll Cardiol* 2014; 63: 636–646.
  50. Townsend RR. Arterial stiffness in CKD: a review. *Am J Kidney Dis* 2018; 73: 240–247.
  51. Allon M, Greene T, Dember LM, et al. Hemodialysis Fistula Maturation Study Group. Association between preoperative vascular function and postoperative arteriovenous fistula development. *J Am Soc Nephrol* 2016; 27: 3788–3795.
  52. McGrogan DG, Stringer S, Cockwell P, et al. Arterial stiffness alone does not explain arteriovenous fistula outcomes. *J Vasc Access* 2018; 19: 63–68.